



Experience in the treatment of Meckel's diverticulum with an open approach versus laparoscopic-assisted supraumbilical in children

Carolina Santamaría Proaño^{1*}, Jorge Oliveros Rivero¹, Johan Aguayo Vistín^{*2}, Diego León Ochoa¹, Daniel Acosta Farina¹

<https://orcid.org/0000-0001-8679-0784>

<https://orcid.org/0000-0002-0824-0864>

<https://orcid.org/0000-0003-3289-4961>

<https://orcid.org/0000-0002-0483-3099>

<https://orcid.org/0000-0002-9655-2824>

1. Pediatric Surgery Postgraduate, Faculty of Medicine, Universidad Católica Santiago de Guayaquil.
2. Department of Pediatric Surgery, Children's Hospital Dr. Roberto Gilbert Elizalde, Guayaquil-Ecuador.

Abstract

Received: June 5; 2022
Accepted: July 27; 2022
Published: August 18; 2022
Editor: Dr. Francisco Xavier Jijón Letort.

Cite:

Santamaría C, Oliveros J, Aguayo J, León D, Acosta D. Experience in the treatment of Meckel's diverticulum with an open approach versus laparoscopic-assisted supraumbilical in children. *Revista Ecuatoriana de Pediatría* 2022;23(2):101-109 doi: <https://doi.org/10.52011/162>

 Copyright Santamaría C et al. This article is distributed under the [Creative Commons CC BY-NC-SA 4.0 Attribution License](https://creativecommons.org/licenses/by-nc-sa/4.0/), which permits non-commercial use and redistribution provided by the source, and the original author is cited.

Introduction: Meckel's diverticulum (M'sD) is the most common congenital intestinal malformation diagnosed intraoperatively and requires surgical resolution once the diagnosis is known. The present study describes the experience in the open and laparoscopic surgical treatment of M'sD.

Methodology: This cross-sectional - retrospective study was carried out in children treated at the Dr. Roberto Gilbert Elizalde Children's Hospital, Guayaquil - Ecuador, for over eight years with a diagnosis of Meckel's diverticulum; variables such as age, sex, symptoms, post-surgical diagnosis, surgical technique, hospital stay, complications, biopsy results, clinical presentation are analyzed. Univariate descriptive statistics are used.

Results: 81 cases were analyzed, 52 men (64%), 25 infants (31%), 23 adolescents (28%). 50 cases (62%) presented as acute abdomen, and 17 cases (21%) presented as intestinal hemorrhage. Incidental M'sD during acute appendicitis was performed incidentally in 23 cases (52%). 67 cases (83%) underwent open surgery, and 14 (17%) underwent combined surgery. Complications were 8/67 cases (11.9%) in open surgery and 1/14 cases (7.1%) in combined surgery (P=0.60).

Conclusion: Laparoscopic resection of M'sD did not increase the risk of morbidity or operative time.

Keywords:

MESH: Infant, Premature; Risk Factors; Mortality; Meckel Diverticulum; Laparoscopy; Peritoneal Cavity.

* Corresponding author.

Introduction

Meckel's diverticulum (M'sD) is the most common congenital intestinal malformation; it originates from the omphalomesenteric duct and has a prevalence of 2% in the general population [1]. It is located in the terminal ileum between 40 and 130 centimeters from the ileocecal valve at the antimesenteric border [2, 3]. More common in men than in women 1.5:1-4:1 [4-8]. M'sD is generally asymptomatic [9]; the symptoms that have been described in children are gastrointestinal bleeding (25.3%) manifested by ulceration of the small intestine; intestinal obstruction (47%) due to intussusception, volvulus, tumor or incarcerated hernia; and diverticulitis (19.5%) due to diverticular obstruction of inflammatory tissue or other foreign bodies, which can cause perforation and peritonitis [10-12].

Only 11% of patients receive a correct preoperative diagnosis of M'sD [13], but most are diagnosed intraoperatively [14]. The traditional treatment is excision by laparotomy, either by segmental resection of the small intestine or wedge resection and anastomosis. Currently, minimally invasive surgery with excision and anastomosis or wedge resection is performed after removing the diverticulum from the abdominal cavity through the umbilical incision [15, 16]. Additionally, laparoscopic stapling devices allow intracorporeal diverticulectomy [17-19].

According to the literature reviewed, no consensus has been described on what type of surgical technique to use in patients with symptomatic or asymptomatic M'sD. It is also essential to evaluate the evolution and complications of patients undergoing open and laparoscopic surgery.

This study describes a single center's experience treating Meckel's diverticulum with an open versus laparoscopic-assisted supraumbilical approach in children.

Population and methods

Design of the investigation

This is an observational, cross-sectional, retrospective study.

Scenery

The study was conducted in the surgery service of the Dr. Roberto Gilbert Elizalde Children's Hospital of the

Benevolent Board of Guayaquil, Ecuador. The study period was from January 1, 2012, to December 31, 2020.

Inclusion criteria

Pediatric patients with Meckel's diverticulum in its three clinical presentations, intestinal obstruction, gastrointestinal bleeding, and diverticulitis, who were managed with two surgical techniques, entered the study. Those patients diagnosed with M'sD incidentally but who had not attended medical control were excluded from the study, and participants with incomplete records were excluded from the analysis.

Studio size

The population was made up of patients admitted to the surgery service of the institution. The sample calculation was nonprobabilistic, census type, where all possible cases that can be analyzed are included.

Variables

The variables were age (grouped into four categories, infants, preschoolers, school children, and adolescents), sex, symptoms, postoperative diagnosis, surgical technique performed, hospital stay, complications, and biopsy results. According to the surgery performed, we classified them into open surgery and combined surgery according to their presentation: intestinal hemorrhage, intestinal obstruction, diverticulitis, and M'sD as incidental findings. Long MDs were classified as having a height:diameter ratio (HDR height:diameter ratio) \geq two and short ones with HDR $<$ 2. Therefore, those greater than 2 cm were classified as wide bases, and those less than 2 cm were classified as small bases; pedunculated those that presented a pedicle in their structure.

Data sources/measurement

The data were collected from the clinical history in a form designed exclusively for that purpose. The institutional electronic system was used for case investigation. In the patients treated by open surgery, an exploratory laparotomy was performed with a supra-infra-median umbilical incision, the presence of the M'sD was identified, and a decision was made to en bloc resection with end-to-end anastomosis in two planes or wedge resection of Meckel's diverticulum with transverse raffia. In two planes with monofilament or braided sutures (absorbable or not), depending on

the surgeon's experience, an underwater tightness test was used to check the impermeability of the suture and closure by planes of the abdominal wall.

In cases of combined surgery, diagnostic laparoscopy was performed with the placement of a trocar at the supraumbilical level, one in the left flank and the other in the right flank, the latter varied. Depending on the case, it was placed in the left iliac fossa, with general visualization of the peritoneal cavity. Once the M'sD was located, it was exteriorized through the supraumbilical port wound, and an en bloc resection with end-to-end anastomosis or wedge resection of the M'sD with primary raffia with monofilament or braided suture, described above, was chosen, according to the trans-surgical characteristics found. The absence of leaks in the sutures was verified with a hermeticity test, then intestinal loops were re-entered into the abdominal cavity, and a plane closure of the abdominal wall was performed.

Statistical method

In the initial phase, the data analysis is univariate and descriptive with frequencies and percentages. Proportions are compared with the chi-square test. The statistical package SPSS v.22 (IBM Corp., Armonk, NY.) was used for the analysis.

Results

Eighty-one patients were analyzed (Figure 1).

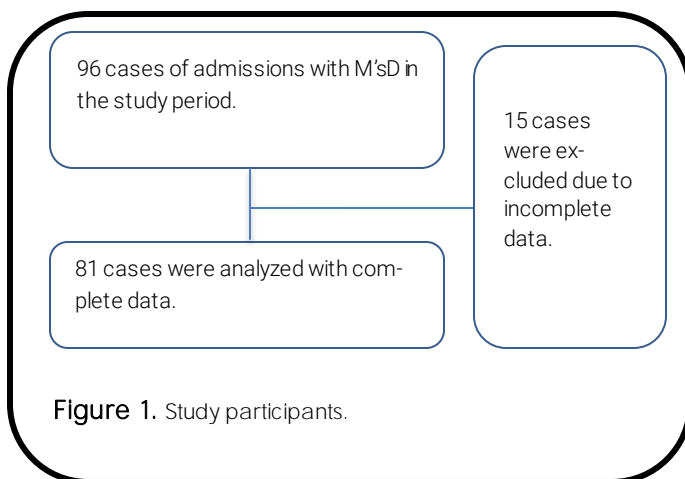


Figure 1. Study participants.

General characteristics of the study sample

The average age of diagnosis was 0.6 years (range 0.05-17 years). According to the age group, infants

with 25 (30.8%) patients and adolescents with 23 cases (28.4%) predominated (Table 1). The predominant symptomatology was abdominal pain, followed by vomiting and gastrointestinal bleeding, as detailed in Table 1.

Among the postoperative findings, incidental M'sD was found in 44 patients (54.32%), of which 23 (52.27%) presented acute appendicitis verified by biopsy; 5 (11.36%) had intussusception, 5 (11.36%) patients with adnexal pathology such as ovarian and para tubal cysts, 3 (6.81%) with adherence syndrome due to previous surgery, 2 (4.54%) had intestinal obstruction due to roundworms or seeds and 2 (4.54%) with a diagnosis of anorectal malformation, in addition to 4 (9.09%) patients who presented other diagnoses. The patients who presented complications of the natural evolution of the M'sD represented 37%, and they were found to have intestinal obstruction, diverticulitis, and intestinal hemorrhage. Patients were diagnosed with M'sD as a trans-surgical finding in previous surgery and were scheduled for diverticulectomy, as described in Table 2.

Table 1. General characteristics of patients with M'sD.

	n = 81	%
Age		
infants	25	31%
Preschool	16	20%
School	17	21%
Teen	23	28%
Sex		
Woman	29	36%
Men	52	64%
Symptoms		
Abdominal pain	fifty	62%
Threw up	35	43%
intestinal bleeding	17	21%
Classification of clinical presentation		
Intestinal obstruction	14	17%
intestinal bleeding	17	21%
Acute abdomen	15	62%

Surgical procedures

Sixty-seven (82.71%) patients were operated on by the open technique, of which 52 (78%) patients underwent resection and end-to-end anastomosis, of which 41 (79%) were wide-based, 8 (15%) were small-based, and 3 (6%) were pedunculated; 15 (22%) patients underwent wedge resection of the M'sD, of which 3 (20%) were wide-based and 12 (80%) were small-based.

Table 2. Patients with incidental M'sD and complications

Post-surgical diagnosis	Open surgery	Combined surgery	Total	%
Incidental M'sD n=43 (54%)				
Acute appendicitis	23	0	23	52
Intussusception	4	1	5	11
Adnexal pathology	5	0	5	11
Adherence syndrome	3	0	3	7
Intestinal obstruction (roundworms/seeds)	2	0	2	5
Anorectal malformation	2	0	2	5
Others (undescended testis, omphalocele, duodenal membrane intestinal atresia, intestinal atresia with volvulus, occlusive bridle)	4	0	4	9
Intestinal obstruction n=13 (16%)				
Intestinal volvulus due to M'sD	3	1	4	31
Plastron M'sD	4	0	4	31
Obstructive band due to M'sD	2	1	3	23
Intussusception	2	0	2	15
Diverticulitis n=5 (6%)				
Inflamed dom	4	0	4	80
Perforated dom	1	0	1	20
Intestinal bleeding n= 12 (15%)				
Intestinal bleeding	5	7	12	15
Finding in previous surgery n=7 (9%)				
Finding in previous surgery	3	4	7	9

In the combined laparoscopic technique, 14 (17%) cases were open surgery, 11 (79%) of these underwent in bloc resection, and 8 (73%) with anastomosis; a wide base of M'sD was found, and 3 (27%) a small base; 3 (21%) patients underwent wedge resection, in whom 2 (67%) had a small base and 1 (33%) had a wide base; and 1 (7%) patient who started as combined resection was decided to convert to exploratory laparotomy due to perforation of the M'sD.

The characteristics of the diverticular base were described in the trans-surgical findings as wide at 53

Table 3. Patients with M'sD according to clinical presentation

DoM basis	Patients		Open surgery				Combined surgery			
	Patients	%	Block N=52	Cradle N=15	Patients N=67	%	Block N=11	Cradle N=3	Patients N=14	%
Wide	53	65	41	3	44	66	8	1	9	64
Small	25	31	8	12	20	30	3	two	5	36
Pedunculated	3	4	3	0	3	4	0	0	0	0

Table 4. Patients with M'sD according to postsurgical complications.

Complications	Open surgery				Combined surgery			
	Block	Cradle	Total	%	Block	Cradle	Total	%
Wound infection	3		3	38	0	0	0	0
Adherence syndrome	3	1	4	15	1	0	1	1
Intussusception	1		1	12	0	0	0	0

(65%), 25 (31%) with a small base, and 3 (4%) were pedunculated (Table 3). The average surgical time for the open technique was 130 min (range 50-210 min), and for the combined technique, the average was 170 min (range 65-275 min).

Postsurgical evolution

The hospital stay for the open technique had an average of 10.91 (range 2 - 60 days), and for the combined technique, it had an average of 10.1 (range 8 - 12 days).

Postsurgical complications

Nine (11.1%) postsurgical complications were found in the total number of patients operated on using the two techniques described; in the open technique, there were 8 (10%), of which 4 (50%) presented adherence syndrome, 3 (38%) patients manifested infection of the surgical wound, and in 1 (12%) patient, an intestinal invagination was found. In the combined technique, there was 1 (1%) complication due to intestinal obstruction due to adherence syndrome, without statistical significance ($P=0.606$) (Table 4).

Biopsy results

The histopathological study only reported 21 of the 81 patients with ectopic tissue in situ, of which gastric tissue was reported in 11 (14%) samples, intestinal tissue in 8 (10%) reports, 2 (3%) reports with pancreatic tissue, and 60 patients whose pathology report did not specify the type of tissue in the biopsy.

Discussion

In published studies, M'sD occurs more frequently in males and infants (≤ 1 year) [20-21] with a male:female ratio of 2:1 and 4:1, respectively. In our research, it is those under two years old or infants followed by adolescents and with a 2:1 ratio.

According to the clinic presented in the M'sD, the most common symptom is abdominal pain in the lower abdominal area. In addition, bloody stools, followed by nausea and vomiting [22, 23.] In the present report, they were abdominal pain, followed by vomiting and gastrointestinal hemorrhage that presented bloody stools.

In a pediatric series of 286 patients (1 day to 15 years of age), 19% of MDs were detected incidentally [24]; in the present case, 54% of patients were found to have incidental findings.

In a systematic review of the complications inherent to the chronology of the pathology of M'sD, 39.5% corresponded to intestinal obstruction, 44% to gastrointestinal hemorrhage, and 22.5% to diverticulitis [9]. In the present study, 16% presented intestinal obstruction, 15% gastrointestinal hemorrhage, and 6% diverticulitis, corresponding to 37% of patients who presented complications.

Pediatric minimally invasive surgery is not yet the surgical standard for most M'sD resection processes; 49.3% of cases were approached laparoscopically because it requires the availability of instruments of appropriate size according to age, more perfect working space, and less potential for physiologic disturbances related to carbon dioxide insufflation, so it is preferred to use in older children and leave the technique open for younger ones [25]. In the present study, open surgery was performed in 83% of patients; 78% of these patients underwent intestinal resection and end-to-end anastomosis, and 22% underwent wedge resection. In the combined technique, 17% of which 79% underwent resection and terminal anastomosis, and 21% underwent wedge resection. This technique also allowed for palpation of Meckel's diverticulum, helping to rule out any thickening of the base and evaluating for the presence of any ectopic gastric mucosa [2-6].

It is essential to decide the indications for laparoscopic exploration and evaluate the resection of

the incidental M'sD. The optimal treatment strategy is determined by determining the following risk factors: (1) patient age < 50 years, (2) male sex, (3) diverticulum length > 2 cm, and (4) ectopic or abnormal features within a diverticulum [3, 27, 28]. Taurus et al. [9] suggested resection of a normal-appearing M'sD in each case of appendectomy or laparotomy/laparoscopy for an acute abdomen to avoid secondary complications [9]. Although the overall risk of tumors in M'sD is low, there is evidence of a high risk of neoplasia in the ileum according to the Surveillance study [29], which states that the benefits of resection of this area of high risk of cancer outweigh risks [29]. In this study, incidental resection was performed in 54% of the patients, of whom 52% presented appendicitis, 11% intussusception, 11% adnexal pathology, 7% adhesion syndrome due to previous surgery, and 5% intestinal obstruction due to another unrelated cause. With the M'sD, 5% with anorectal malformation and 9% are cataloged in other diagnoses.

Varcoe et al. [30]. found that all long M'sDs with a height:diameter ratio (HDR height:diameter ratio) ≥ 2 had heterotopic gastric mucosa at the tip of the diverticulum, but in short M'sDs with HDR < 2 , heterotopic gastric mucosa involved the base of the M'sD [30]. Therefore, we based ourselves on classifying those larger than 2 cm on wide bases; as has been described, 65% were wide-based, 31% were small-based, and 4% pedunculated.

The times between laparoscopy and open surgery seem comparable, with an operative time of only six minutes more in laparoscopic cases [31]. The results were similar to the surgical times of the present study, where a mean of 130 min was identified for the open technique and 170 min for the combined technique, taking into account the bias time in laparoscopic instrumentation and the surgeon's expertise; the combined technique has a good average.

The study by Huang et al. [9] reported a 5% complication rate for Meckel resection. Intestinal obstruction accounts for 26-53% of complications [2,9,20,21]. The most common complications were surgical site infection, postoperative ileus, and anastomotic leakage, which are complications of any small bowel surgery [32]. In the present study, 11% of

complications were found, of which 88% corresponded to the open technique, predominating intestinal obstruction due to adhesion syndrome in 50%, followed by surgical wound infection in 38%, and 12% presented an intestinal intussusception. In the assisted technique, a complication corresponding to 1% was evidenced, with intestinal obstruction due to adhesion syndrome. When comparing the complications presented in both techniques, no statistically significant difference was found ($P: 0.606$).

Stănescu [22]. The histopathological results are described according to the four types of mucosa: ectopic tissue with 34%, gastric with 25%, pancreatic with 6.8%, and intestinal with 2.3% [2]. In this report, 14% was gastric tissue, 10% intestinal, and 2% pancreatic, different results from the referenced bibliography.

As a limitation, it is essential to mention that this study is retrospective and not randomized, so we suggest conducting prospective studies with a larger number of patients.

Conclusions

Laparoscopic resection of M'sD did not increase the risk of morbidity, operative time, or complications.

Abbreviations

M'sD: Meckel's diverticulum.

Supplementary information

Supplementary materials are not declared.

Acknowledgments

The teaching team members of the "Dr. Roberto Gilbert Elizalde" Children's Hospital are acknowledged and thanked for their collaboration in this study.

Author contributions

Carolina Santamaria Proaño: Conceptualization, Data Retention, Funding, Research, Resources, Software, Writing - original draft.
Jorge Oliveros Rivero: conceptualization, data conservation, supervision, fundraising, research, resources, and writing: review and editing.

References

1. Sagar J, Kumar V, Shah DK. Meckel's diverticulum: a systematic review. *JR Soc Med.* 2006 Oct;99(10):501-5. DOI:10.1258/jrsm.99.10.501. Erratum in: *JR Soc Med.* 2007 Feb;100 (2):69. PMID: [17021300](#); PMCID: PMC1592061.
2. Stănescu GL, Pleșea IE, Diaconu R, Gheonea C, Sabetay C, Țișteea D, Niculescu EC. Meckel's diverticulum in children, clinical and pathological aspects. *Rom J Morphol Embryol.* 2014;55 (3 Suppl):1167-70. PMID: [25607401](#).
3. Park JJ, Wolff BG, Tollefson MK, Walsh EE, Larson DR. Meckel diverticulum: the Mayo Clinic experience with 1476 patients (1950-2002). *Ann Surg.* 2005Mar;241 (3):529-33. DOI:10.1097/01.sla.0000154270.14308.5f. PMID: [15729078](#); PMCID: PMC1356994.
4. Hansen CC, Søreide K. Systematic review of epidemiology, presentation, and management of Meckel's diverticulum in the 21st century. *Medicine (Baltimore).* 2018

Johan Aguayo Vistin: Conceptualization, Data Conservation, Supervision, Fund Acquisition, Research, Resources.

Diego León Ochoa: Curation of data, research, acquisition of funds, supervision, methodology.

Daniel Acosta Farina: conceptualization, data conservation, supervision, visualization, methodology.

All authors read and approved the final version of the manuscript.

Financing

The authors financed the expenses incurred in the production of this research. Laboratory expenses and cabinet tests, including X-rays, are part of the usual activity of the neonatology service and do not constitute an additional expense to the patient or relatives.

Availability of data and materials

The data sets generated and analyzed during the current study are not publicly available due to participant confidentiality but are available through the corresponding author upon reasonable academic request.

Statements

Ethics committee approval and consent to participate

It was not required for a retrospective database study.

Publication consent

It does not apply to studies that do not publish MRI/CT/Rx images or physical examination photographs.

Conflicts of interest

The authors declare no conflicts of interest.

Author Information

Carolina Santamaria Proaño - Postgraduate doctor of Pediatric Surgery, Santiago de Guayaquil Catholic University, Children's Hospital. Dr. Roberto Gilbert Elizalde. Guayaquil, Ecuador. ORCID: 0000-0001-8679-0784, carosanpro@gmail.com

Jorge Oliveros Rivero - Postgraduate doctor of Pediatric Surgery, Santiago de Guayaquil Catholic University, Children's Hospital. Dr. Roberto Gilbert Elizalde. Guayaquil, Ecuador. ORCID: 0000-0002-0824-0864, jorgealejandrooliveros@hotmail.com

Johan Aguayo Vistin - Postgraduate doctor of Pediatric Surgery, Santiago de Guayaquil Catholic University, Children's Hospital. Dr. Roberto Gilbert Elizalde. Guayaquil, Ecuador. ORCID: 0000-0003-3289-4961, johan88@hotmail.es

Diego León Ochoa - Physician treating Pediatric Surgery. Children's Hospital. Dr. Roberto Gilbert Elizalde. Guayaquil, Ecuador. ORCID: 0000-0002-0483-3099, dieo74@hotmail.com

Daniel Acosta Farina - Head of the Department of Pediatric Surgery. Children's Hospital. Dr. Roberto Gilbert Elizalde. Postgraduate Director of Pediatric Surgery Universidad Católica Santiago de Guayaquil, Guayaquil-Ecuador. ORCID: 0000-0002-9655-2824, acofa111@yahoo.es.

- Aug;97 (35):e12154. DOI: 10.1097/MD.00000000000012154. PMID: [30170459](#); PMCID: PMC6392637.
5. Keese D, Rolle U, Gfroerer S, Fiegel H. Symptomatic Meckel's Diverticulum in Pediatric Patients—Case Reports and Systematic Review of the Literature. *Front Pediatr*. 2019 June 26;7:267. DOI: 10.3389/fped.2019.00267. PMID: [31294008](#); PMCID: PMC6606722.
 6. Francis A, Kantarovich D, Khoshnam N, Alazraki AL, Patel B, Shehata BM. Pediatric Meckel's Diverticulum: Report of 208 Cases and Review of the Literature. *Fetal Pediatric Pathol*. 2016;35 (3):199-206. DOI: 10.3109/15513815.2016.1161684. Epub 2016 April 11. PMID: 27064958.
 7. Alemayehu H, Hall M, Desai AA, St Peter SD, Snyder CL. Demographic disparities of children presenting with symptomatic Meckel's diverticulum in children's hospitals. *Pediatric Surg Int*. 2014 Jun;30 (6):649-53. DOI:10.1007/s00383-014-3513-y. Epub 2014 May 9. PMID: [24811048](#).
 8. Ruscher KA, Fisher JN, Hughes CD, Neff S, Lerer TJ, Hight DW, Bourque MD, Campbell BT. National trends in the surgical management of Meckel's diverticulum. *J Pediatr Surg*. 2011 May;46 (5):893-6. DOI: 10.1016/j.jpedsurg.2011.02.024. PMID: [21616248](#).
 9. Keese D, Rolle U, Gfroerer S, Fiegel H. Symptomatic Meckel's Diverticulum in Pediatric Patients—Case Reports and Systematic Review of the Literature. *Front Pediatr*. 2019 June 26;7:267. DOI: 10.3389/fped.2019.00267. PMID: [31294008](#); PMCID: PMC6606722.
 10. Leijonmarck CE, Bonman-Sandelin K, Frisell J, Räf L. Meckel's diverticulum in the adult. *Br J Surg*. 1986 Feb;73 (2):146-9. DOI:10.1002/bjs.1800730225. PMID: [3484984](#).
 11. Symeonidis N, Kofinas A, Psarras K, Pavlidis E, Pavlidis T. Meckel's Diverticulum Enterolith: An Extremely Rare Cause of Intestinal Obstruction. *J Clin Diagn Res*. 2017 Apr;11 (4):PD11-PD12. DOI: 10.7860/JCDR/2017/25941.9751. Epub 2017 April 1. PMID: [28571210](#); PMCID: PMC5449856.
 12. Bidarmaghz B, McGregor H, Raufian K, Tee CL. Perforation of the Meckel's diverticulum with a chicken bone: a case report and literature review. *Surg Case Rep*. 2019 Feb 1;5 (1):15. DOI: 10.1186/s40792-019-0577-x. PMID: [30707313](#); PMCID: PMC6361192.
 13. Kloss BT, Broton CE, Sullivan AM. Perforated Meckel diverticulum. *Int J Emerg Med*. 2010 August 20;3(4):455-7. DOI: 10.1007/s12245-010-0213-9. PMID: [21373322](#); PMCID: PMC3047846.
 14. Garfunkel L, Kaczorowski J, Christy C. Pediatric Clinical Advisor E-book: Instant Diagnosis and Treatment, Elsevier Health Sciences, 2007 July 5.
 15. Papparella A, Nino F, Noviello C, Marte A, Parmeggiani P, Martino A, Cobellis G. Laparoscopic approach to Meckel's diverticulum. *World J Gastroenterol*. 2014 Jul 7;20 (25):8173-8. DOI: 10.3748/wjg.v20.i25.8173. PMID: [25009390](#); PMCID: PMC4081689.
 16. Prasad TR, Chui CH, Jacobsen AS. Laparoscopic -assisted resection of Meckel's diverticulum in children. *JLS*. 2006 Jul-Sep;10 (3):310-6. PMID: [17212886](#); PMCID: PMC3015699.
 17. Glenn IC, El -Shafy IA, Bruns NE, Muenks EP, Duran YK, Hill JA, Peter SDS, Prince JM, Lipskar AM, Ponsky TA. Simple diverticulectomy is adequate for management of bleeding Meckel diverticulum. *Pediatric Surg Int*. 2018 Apr;34 (4):451-455. DOI: 10.1007/s00383-018-4239-z. Epub 2018 February 19. PMID: [29460177](#).
 18. Robinson JR, Correa H, Brinkman AS, Lovvorn HN 3rd. Optimizing surgical resection of the bleeding Meckel diverticulum in children. *J Pediatr Surg*. 2017 Oct;52(10):1610-1615. DOI: 10.1016/j.jpedsurg.2017.03.047. Epub 2017 March 23. PMID: [28359587](#); PMCID: PMC5610599.
 19. Palanivelu C, Rangarajan M, Senthilkumar R, Madankumar MV, Kavalakat AJ. Laparoscopic management of symptomatic Meckel's diverticula: a simple tangential stapler excision. *JLS*. 2008 Jan-Mar;12(1):66-70. PMID: [18402742](#); PMCID: PMC3016022.
 20. Keese D, Rolle U, Gfroerer S, Fiegel H. Symptomatic Meckel's Diverticulum in Pediatric Patients—Case Reports and Systematic Review of the Literature. *Front Pediatr*. 2019 June 26;7:267. DOI: 10.3389/fped.2019.00267. PMID: [31294008](#); PMCID: PMC6606722.
 21. Zani A, Eaton S, Rees CM, Pierro A. Incidentally detected Meckel diverticulum: to resect or not to resect? *Ann Surg*. 2008 Feb;247 (2):276-81. DOI: 10.1097/SLA.0b013e31815aaaaf8. PMID: 18216533.
 22. St - Vil D, Brandt ML, Panic S, Bensoussan AL, Blanchard H. Meckel's diverticulum in children: a 20-year review. *J Pediatr Surg*. 1991 Nov;26 (11):1289-92. DOI: 10.1016/0022-3468(91)90601-o. PMID: [1812259](#).
 23. Lindeman RJ, Søreide K. The Many Faces of Meckel's Diverticulum: Update on Management in Incidental and Symptomatic Patients. *curr Gastroenterol Rep*. 2020 Jan 13;22 (1):3. DOI: 10.1007/s11894-019-0742-1. PMID: [31930430](#).

24. Duan X, Ye G, Bian H, Yang J, Zheng K, Liang C, Sun X, Yan X, Yang H, Wang X, Ma J. Laparoscopic vs. laparoscopically assisted management of Meckel's diverticulum in children. *Int J Clin Exp Med*. 2015 January 15;8(1):94-100. PMID: [25784978](#); PMCID: PMC4358433.
25. Ezekian B, Leraas HJ, Englum BR, Gilmore BF, Reed C, Fitzgerald TN, Rice HE, Tracy ET. Outcomes of laparoscopic resection of Meckel's diverticulum are equivalent to open laparotomy. *J Pediatr Surg*. 2019Mar;54 (3):507-510. DOI: 10.1016/j.jpedsurg.2018.03.010. Epub 2018 March 15. PMID: 29661575.
26. Chan KW, Lee KH, Wong HY, Tsui SY, Wong YS, Pang KY, Mou JW, Tam YH. Laparoscopic excision of Meckel's diverticulum in children: what is the current evidence? *World J Gastroenterol*. 2014 Nov 7;20 (41):15158-62. DOI:10.3748/wjg.v20.i41.15158. PMID: [25386065](#); PMCID: PMC4223250.
27. Groebli Y, Bertin D, Morel P. Meckel's diverticulum in adults: retrospective analysis of 119 cases and historical review. *Eur J Surg*. 2001Jul;167 (7):518-24. DOI: 10.1080/110241501316914894. PMID: [11560387](#).
28. Robijn J, Sebrechts E, Miserez M. Management of incidentally found Meckel's diverticulum a new approach: resection based on a Risk Score. *Act Chir Belgium*. 2006 Jul-Aug;106 (4):467-70. DOI: 10.1080/00015458.2006.11679933. PMID: [17017710](#).
29. Sandvik OM, Søreide K, Gudlaugsson E, Kvaløy JT, Søreide JA. Epidemiology and classification of gastroenteropancreatic neuroendocrine neoplasms using current coding criteria. *Br J Surg*. 2016 Feb;103 (3):226-32. DOI: 10.1002/bjs.10034. Epub 2015 October 29. PMID: [26511392](#); PMCID: PMC5061026.
30. Varcoe RL, Wong SW, Taylor CF, Newstead GL. Diverticulectomy is the inadequate treatment for short Meckel's diverticulum with heterotopic mucosa. *ANZ J Surg*. 2004 Oct;74 (10):869-72. DOI: 10.1111/j.1445-1433.2004.03191.x. PMID: [15456435](#).
31. Ezekian B, Leraas HJ, Englum BR, Gilmore BF, Reed C, Fitzgerald TN, Rice HE, Tracy ET. Outcomes of laparoscopic resection of Meckel's diverticulum are equivalent to open laparotomy. *J Pediatr Surg*. 2019Mar;54 (3):507-510. DOI: 10.1016/j.jpedsurg.2018.03.010. Epub 2018 March 15. PMID: [29661575](#).
32. Lin XK, Huang XZ, Bao XZ, Zheng N, Xia QZ, Chen CD. Clinical characteristics of Meckel diverticulum in children: A retrospective review of a 15-year single-center experience. *Medicine (Baltimore)*. 2017 Aug;96 (32):e7760. DOI: 10.1097/MD.0000000000007760. PMID: [28796070](#); PMCID: PMC5556236.

DOI: Digital Object Identifier PMID: PubMed Identifier SU: Short URL

Editor's note

The Ecuadorian Journal of Pediatrics remains neutral concerning jurisdictional claims on published maps and institutional affiliations.